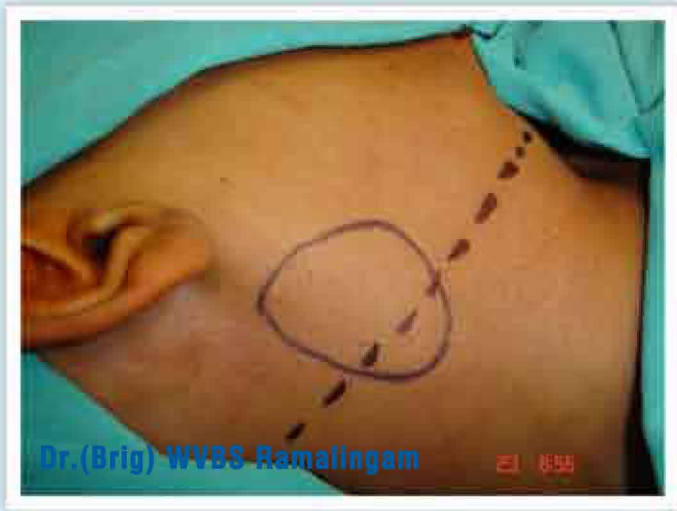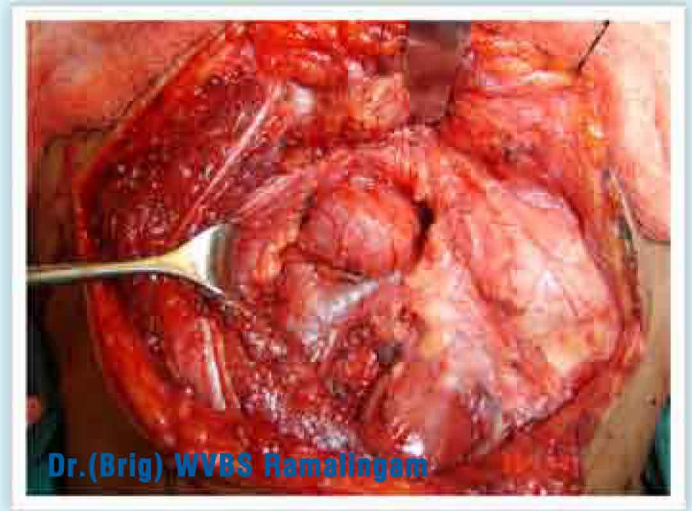




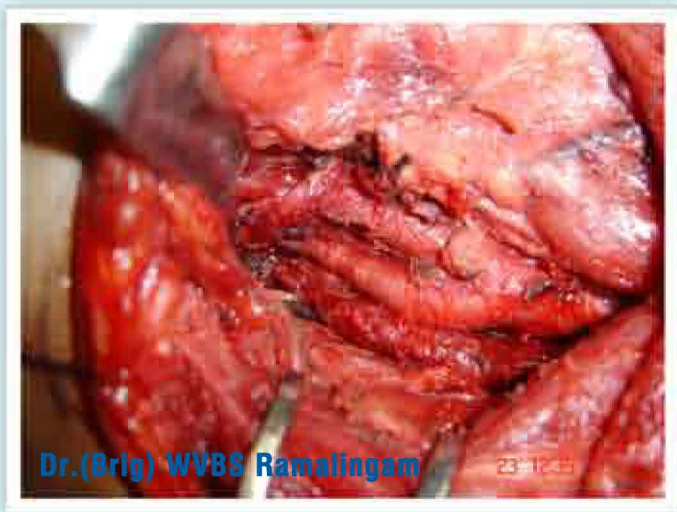## GLOMUS VAGALE



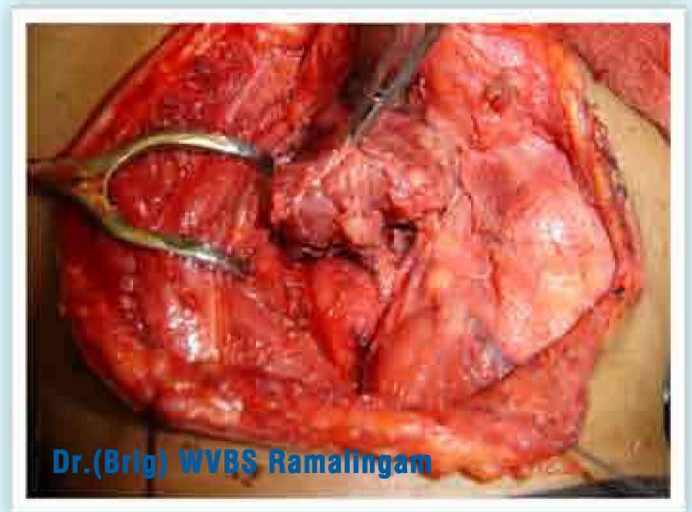
A CASE of GLOMUS VAGALE



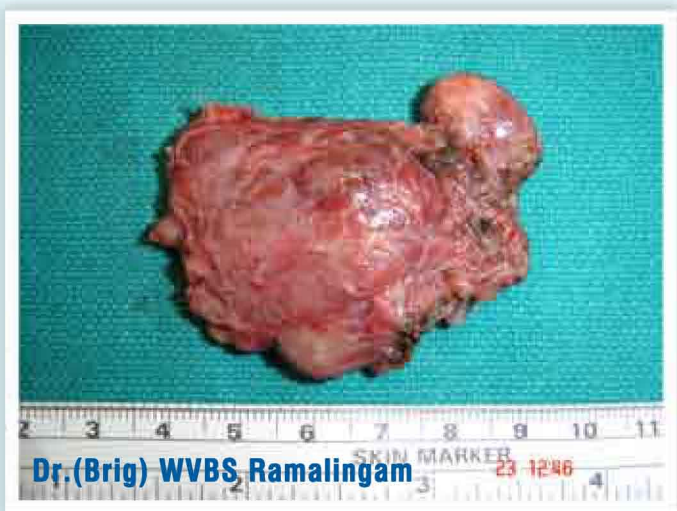TUMOUR EXPOSED



CAROTID ARTERY EXPOSED



TUMOUR BEING REMOVED



EXCISED TUMOUR